

Imagery of the lymphatic system by means of echography and magnetic resonance.

Lympho-Phlebology Unit, Haute Ecole P.H. Spaak,
O. Leduc, L. Brognard, A. Stenhouse, A. Leduc.

Department of Radiology- CHU Charleroi, E. Fumière, C. Delcour.
Université Libre de Bruxelles, CUB Erasme. F. Wilputte.

Purpose: to first confirm the possible visualisation of the lymphatic collectors by means of an ultrasound head of 13.5Mhz and second to specify in asymptomatic and lymphoedema cases the echogenic characters of the lymphatic collectors.

Method: using cadaverous piglet parts and after rendering the lymphatic collectors opaque (fig.1) we correlated the ultrasound imaging with the MRI. We limited the imaging study to 3 piglets and using 4 legs. Then, we selected 5 asymptomatic human subjects and 5 human subjects affected by lymphoedema on which we were looking for similar ultrasound imaging patterns than the one found on piglets.

Results: The injection of modified Gerota's mass allowed for a precise identification of lymphatic collectors (fig1), which were visualised by skin transparency. The ferromagnetic artefacts generated by the modified Gerota's mass allowed the identification of the lymphatic collectors on MRI. The identification of the piglet lymphatic collectors by means of the ultrasound imaging (fig. 2,4) was correlated with both the MRI (fig.3,5) and dissection. In man, through the use of ultrasound imaging we can detect collectors of small size. These small collectors take the appearance of linear hypodermal hyperechogenic structures along the limb longitudinal axis. The bigger collectors take the appearance of double hyperechogenic lines with a central anechogenic lumen (Fig.6), which at times flows into a lymphnode.

Conclusion:

The lymphatic collectors can be detected by means of ultrasonic head of 13,5 Mhz. However, the detection remains thorny on healthy human subjects.

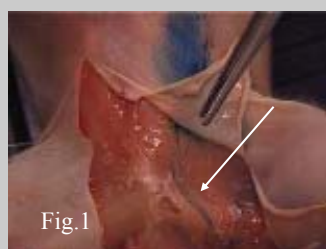

Fig.1

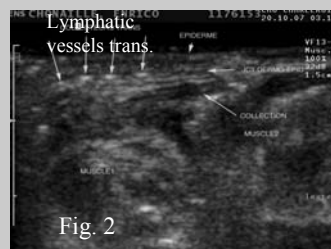

Fig. 2

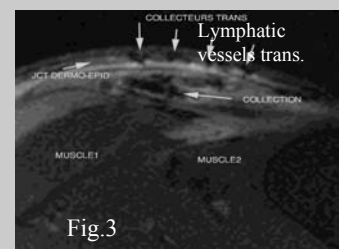


Fig.3

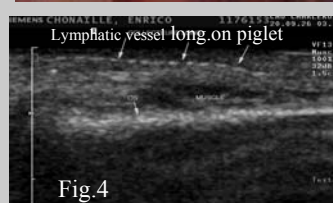


Fig.4

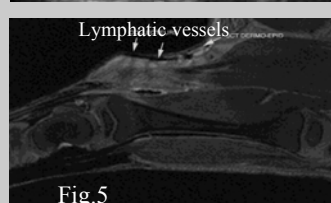

Fig.5

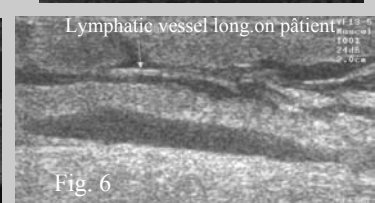


Fig. 6